

## Teaser Bull Preparation by Surgically Made Ventral Prepuce Foramen

Ángel Vázquez Gil\*, Carlos J. de Loyola Oriyés\*, Danays Palacio Collado\*, Alex Resillez Pujal\* and Yenny Asel Pavón Pérez\*\*

\* Faculty of Agricultural Sciences, Ignacio Agramonte Loynaz University of Camagüey, Cuba

\*\* Faculty of Foreign Languages, Ignacio Agramonte Loynaz, University of Camagüey, Cuba

angel.vazquez@reduc.edu.cu

---

### ABSTRACT

This surgical technique (opening of an artificial ventral prepuce orifice) was used to prepare 50 Holstein x Zebu teaser bulls. This study was made at Triangulo 5 and Triangulo 3 cattle companies, and on El Taburete Farm in the province of Camagüey, Cuba. Healing and recovery, surgery time, and costs of medication and surgical materials, were evaluated. Exploratory examination was made ten months after the procedure to verify the general state of the animal and the success of surgery. This technique demonstrated its simplicity, cost effectiveness, and celerity, both in execution and animal recovery. The surgically made ventral prepuce orifice is recommended to cut down production costs of cattle raising, and it could be used in other species of interest as well, like ovine-caprine.

Key words: *sexual libido, surgical technique, bulls, block mounting*

### INTRODUCTION

The utilization of teaser bulls (intact and sterilized males) in artificial insemination projects is the most reliable method to detect estrus (Grissett, 2015). Several techniques developed in the 1960s have been referred to by Franco da Silva, Martins Chaves, Soares Fioravanti, and Eurides and Rabelo (2002), also described for other animal species, like ovines (Tamadon *et al.*, 2010), and caprines (Ponilla de Leon, Lemos Oliveira, and Fernandes de Lima and Pessoa Guerra, 1996). However, many of these methods and techniques have lost their practical value due to violent and/or complex procedures, and the amount of surgical materials needed for teaser preparation in the field. Other methods are not very efficient in estrus detection, since they lead to libido inhibition processes eventually (Gálvez Gálvez, Loyola Oriyés, Avilés Balmaseda, Bertot Valdés, and Rodríguez Rodríguez, 2000).

The purposes of teaser bull preparation are, to sterilize animals, prevent venereal diseases, and maintain elevated libido levels for a long time (Morgan and Dawson, 2008). To achieve that, Franco da Silva *et al.* (2002) mentioned two procedures: one aiming to prevent semen ejaculation, and the other to block mounting, but they not always meet the set goals. The aim of this study

was to describe a technique for teaser bull preparation through a surgically made ventral prepuce foramen.

### MATERIALS AND METHODS

This study was made at Triangulo 5 and Triangulo 3 cattle companies, and on El Taburete Farm in the province of Camagüey, Cuba. Fifty Holstein x Zebu animals were included in the study (14 months old, 150 kg of live weight). The animals were clinically healthy, with bone and muscle integrity, and sexually active. Andrological examination was made to determine or evaluate their future teasing capacity with efficiency. The animals scoring less than four in the libido rating scale (range of 0-10) devised by Chenoweth (1981), were rejected.

#### *Surgical technique*

First, the animal was placed in dorsal decubitus position with extended legs. Then the operative field was disinfected and local anesthetic was applied by infiltration at the site of the incision (3 ml per animal) (Fig. 1).

Fig. 2 shows the sequential photos of the surgical procedure; it started with an atraumatic 30 cm long x 2-3 cm wide cylinder (rubber, plastic or wood) which was introduced 15 cm through the preputial orifice to facilitate the incision in the ventral side of the prepuce. The orifice should be

round (2-3 cm of diameter), through the skin, subcutaneous cellular tissue, muscle layer, and mucosa, to the conduit's span (photos 3 and 4). When the portion of tissue was detached, small incisions were made in the dorsal and ventral mucosa to stimulate healing (photo 5), which is critical for the success of the operation. Then, the mortified cranial mucosa was sutured by cross or Sultan stitching, using chromic catgut No 0 (photos 6 and 7). That way, the normal passage of the penis is blocked in its most cranial portion, forcing it to exit through the surgical orifice during erection. The last step was simple straight suture of the skin, subcutaneous cellular tissue, muscle layer, and mucosa around the incision (photo 8) with silk suture (No. 0), which was withdrawn seven days later.

#### *Surgical instruments*

The tools for minor surgery comprised a needle holder, scalpel handle, scalpel blades, hemostatic Kelly pincers, dissection scissors, scissors, 5 and 10 ml syringes, hypodermic needles (No. 20), and stitch needles.

#### *Surgical material and medication*

The surgical materials used included silk suture thread No 0), suture thread for chromic catgut No. (0), cotton, swabs, and gloves. Medication: eosin (disinfecting), tanogen (healing), antimicrobials (procaine benzylpenicilline), insect repellent, and local anesthetic (lidocaine 2%).

## **RESULTS AND DISCUSSION**

The surgical technique was made quickly and easily, in a short time (7 min and 32 s per animal), slightly lower than the 8-10 m in reported by Gálvez *et al.* (2000), using the penis adherence to the skin technique. Quickness is important to reduce stress that increases susceptibility to infections (Alfonso, 2000). Besides, local anesthetic only reduces the risk of sedative use, as in other more complex techniques, like lateral deviation of the penis and section of the dorsal ligament of penis (Saldivia, Silva, and Vasquez, 1992; Franco da Silva *et al.*, 2002; Arieta-Román, Rodríguez-Orozco, Cano-Flores, Delfín-Beltrán, and Fernández-Figueroa, 2015), which additionally requires fasting in the previous 24 h, thus increasing stress.

During the postoperative process, healing by primary intention was observed in all the cases. The conditions were then optimum for efficient teaser activity 15 days later, which is a comparatively short time in relation to other techniques used today, like penis deviation, with a 4-6 week delay (Rondón Ríos *et al.*, 2008; Grissett, 2015), or lateral implant of the prepuce that lasts 22 days (Rondón Ríos *et al.*, 2008). The time lapse from preparation until use is as short as the one referred to by Carlos *et al.* (1992) with 14 days for the section of dorsal ligament of penis and epididymectomy.

With this technique there is no need to perform vasectomy, since no penetration occurs in the vagina; the erect penis moves downward when the bull tries to mount; therefore, it is impossible to reach the vagina. With other techniques (penile deviation, lateral implant of the prepuce, and adherence of sigmoid flexure), teaser bulls might eventually adapt to their condition and mate, which has been described by several authors (Morgan and Dawson, 2008; Grissett, 2015). This situation has forced additional vasectomy or ablation of the cauda epididymis. However, this procedure does not offer full guarantee because the epididymal conduit has been observed to restore (Tulle, 2011).

After 15 days, all the animals showed adequate healing, without micturition difficulties, and the interruption of the normal path of the penis during erection (Fig. 3), though, complete insurance requires checking out the behavior of every teaser bull with the females.

This surgical technique reduces bleeding considerably, because only a small circular portion of skin and mucosa are extirpated. Hence, it can be performed at any age with no risk of profuse bleeding, in comparison to other more complex operations, such as all variants of penile deviation, adherence of sigmoid flexure, penectomy, dorsal ligament of penis, epididymectomy, and others. The risk of hemorrhage is reduced when surgery is made at younger ages, since vascularization and thickness of the blood vessels are smaller. But the previous and necessary libido test to check the potential as a teaser will be more uncertain if it is made at younger ages (less than 12 months old) because mounting varies with age (Katz and Price, 1986).

## CONCLUSIONS

The surgical technique to make a prepuce foramen is simple and quick, and requires a short recovery time, with low risk of hemorrhage, and few resources. Its use could be useful in other ruminant species of zootechnical interest, like ovines and caprines.

## REFERENCES

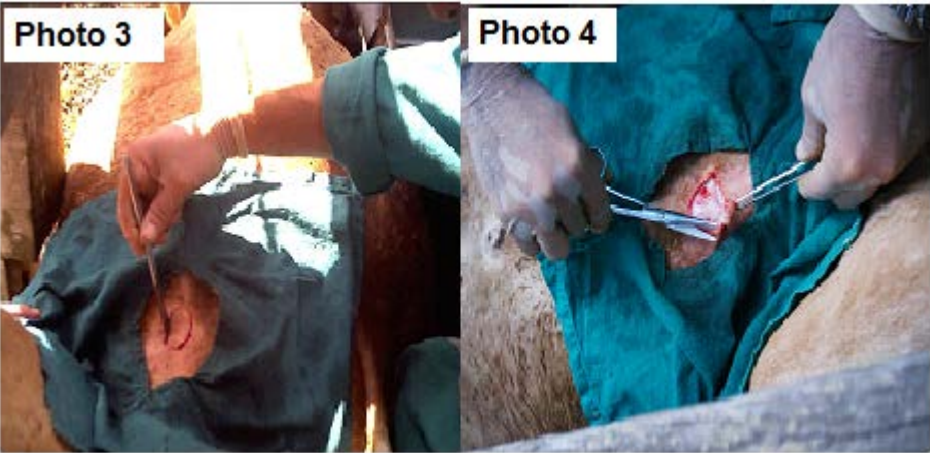
- ALFONSO, O. (2000). *Fisiopatología veterinaria*. La Habana, Cuba: Editorial Félix Varela.
- ARIETA-ROMÁN, R.; RODRÍGUEZ-OROZCO, N.; CANO-FLORES, M.; DELFÍN-BELTRÁN, L. y Fernández-Figueroa, A. (2015). Preparación de toros marcadores, utilizando la técnica modificada de desviación quirúrgica de pene. *Abanico Veterinario*, 5 (1), 35-43.
- CHENOWETH, P. J. (1981). Libido and Mating Behavior in Bulls, Boars and Rams. A review. *Theriogenology*, 16 (2), 155-177.
- FRANCO DA SILVA, L. A.; MARTINS CHAVES, S.; SOARES FIORAVANTI, M. C.; EURIDES, D. y RABELO, R. E. (2002). Complicações de correntes da utilização de acepromazina associada à xilazina na preparação cirúrgica de rufiões bovinos. *Ciência Rural, Santa Maria*, 32 (3), 439-444.
- GÁLVEZ GÁLVEZ, F.; LOYOLA ORIYÉS, C. J.; AVILÉS BALMASEDA, R. G., BERTOT VALDÉS, J. A. y RODRÍGUEZ RODRÍGUEZ, J. A. (2000). Fimosis artificial para la preparación de receladores bovinos. *Rev. prod. anim.*, 12 (1), 107-109.
- GRISSETT, G. (2015). Preparation of Teaser Bulls. In R. M. Hopper (Ed.), *Bovine Reproduction* (First ed., pp. 181-186). Kansas, USA: John Wiley & Sons, Inc.
- KATZ, L. S. y PRICE, E. O. (1986). The Role of Penile Stimulation and Ejaculatory Experience on the Development and Maintenance of Reproductive Behavior in the Bull (*Bos taurus*). *Developmental Psychobiology*, 19 (3), 197-209.
- MORGAN, G. L. y DAWSON, L. J. (2008). Development of Teaser Bulls Under Field Conditions. *Vet. Clin. Food Anim.*, 24 (1), 443-453.
- PONILLA DE LEON, J. I.; LEMOS OLIVEIRA, M. A.; FERNANDES DE LIMA, P. y PESSOA GUERRA, M. M. (1996). Preparação de rufiões caprinos pela fixação da curvatura caudal da flexura sigmóide do pênis. *Ciência Rural*, 26 (2), 241-245.
- RONDÓN RÍOS, G.; REYES ÁVILA, I. R.; SÁNCHEZ GARCÍA, J.; GONZALO-ORDEN, J. M.; FAJARDO RIVERO, H.; VIAMONTES, M. I. et al. (2008). Implantación lateral del prepucio en toros cebuados. Descripción y evaluación de una técnica para la preparación de receladores bovinos. *Revista Electrónica de Clínica Veterinaria*, 3 (6), 1-12.
- SALDIVIA, C., SILVA, O. y VASQUEZ, L. (1992). Sección del ligamento dorsal del pene y epididimectomía en la preparación de toros detectores de celo. *Revista Científica FCV de Luz*, 2 (2), 7-10.
- TAMADON, A.; NIKAHVAL, B.; SEPEHRIMANESH, M.; MANSOURIAN, M.; TABATABAEI NAEINI, A. y NAZIFI, S. (2010). Epididymis Ligation: A Minimally Invasive Technique for Preparation of Teaser Rams. *Veterinary Surgery*, 39 (1), 121-127.
- TULLE, W. (2011). An Alternative Surgical Procedure for the Preparation of Teaser Bulls. *Livestock*, 16 (2), 26-28.

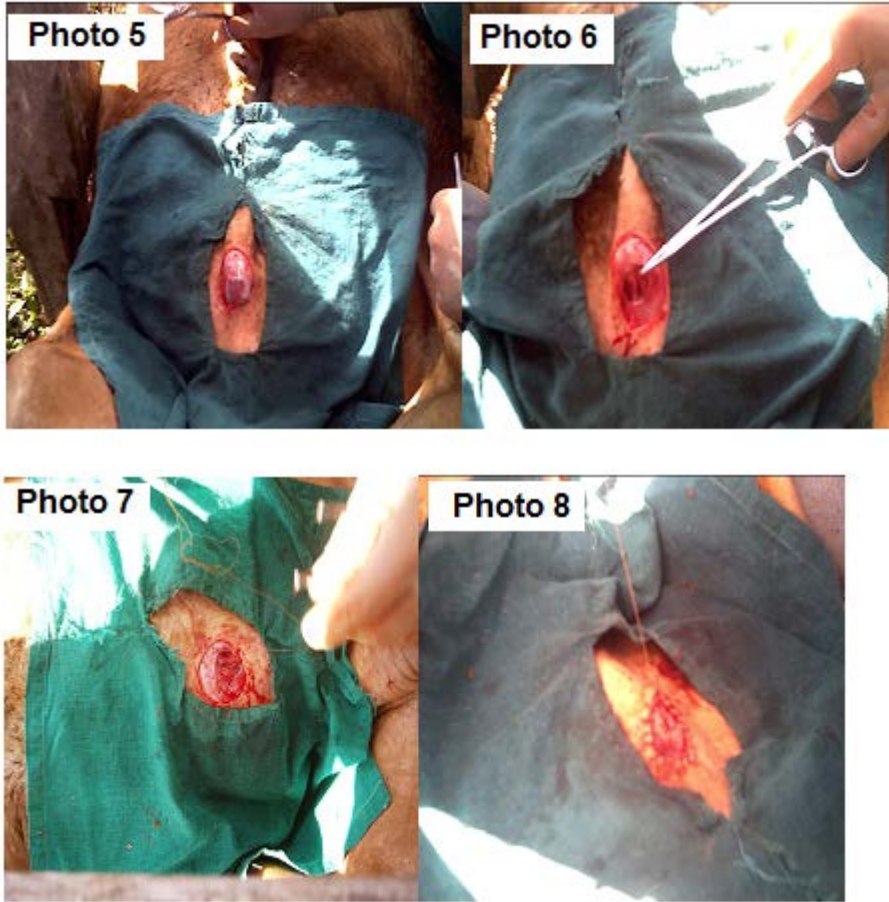
Received: 1-10-2018

Accepted: 1-16-2018

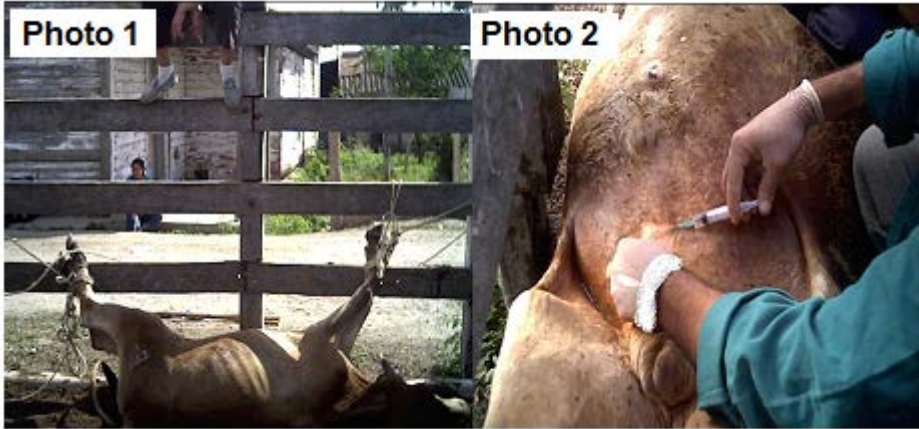

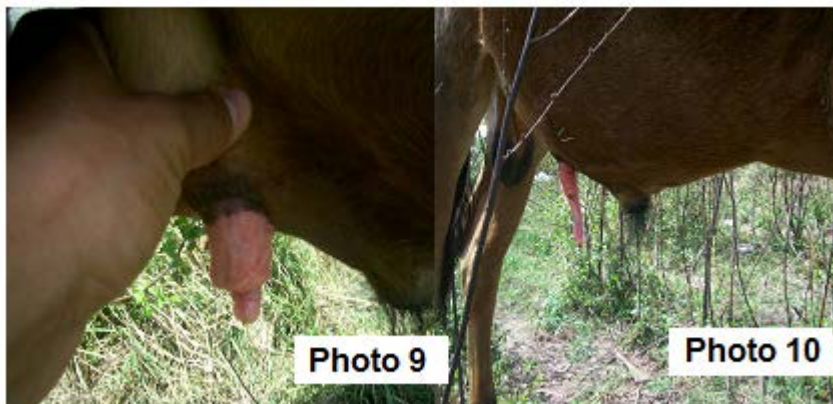Fig. 1. Immobilization (photo 1). Local infiltration with 2% lidocaine (photo 2)





**Fig. 2.** Circular incision on the ventral area of the prepuce, before the resting penis site (photo 3). Exposure of subcutaneous cellular tissue (photo 4). Opening of the prepuce channel with penis exposure (photo 5). Small incisions on the dorsal and ventral mucosa to induce adequate healing (photo 6). Suture of the mucosa to block the passage of penis through the anterior prepuce channel (photo 7). Suture of the skin with subcutaneous tissue and the edge of prepuce channel mucosa (photo 8).



**Fig. 3.** Exploration 10 months after surgery (photos 9 and 10).

